



Physical Examination of Knee Ligament Injuries

Robert D. Bronstein, MD
Joseph C. Schaffer, MD

Abstract

The knee is one of the most commonly injured joints in the body. A thorough history and physical examination of the knee facilitates accurate diagnosis of ligament injury. Several examination techniques for the knee ligaments that were developed before advanced imaging remain as accurate or more accurate than these newer imaging modalities. Proper use of these examination techniques requires an understanding of the anatomy and pathophysiology of knee ligament injuries. Advanced imaging can be used to augment a history and examination when necessary, but should not replace a thorough history and physical examination.

The knee joint is one of the most commonly injured joints in the body. Knee ligament injury and subsequent instability can cause considerable disability. Diagnosis of knee ligament injuries requires a thorough understanding of the anatomy and the biomechanics of the joint. Many specific examination techniques were developed before advanced imaging, and several techniques remain as accurate or more accurate than the new imaging modalities. Advanced imaging (eg, MRI) is appropriate to use as necessary but should not replace the history and physical examination. A survey of patients who obtained a second opinion regarding a knee injury reported that 11% of the previously seen orthopaedic surgeons did not palpate the injured knee and only 37% palpated the contralateral knee.¹

The orthopaedic surgeon should obtain a thorough history before performing a physical examination of the knee. A description of the mechanism of injury allows the surgeon to assess the structures that may have been stressed or compressed. The patient should be queried about previous

injuries because the current injury may be the sequela of a previous injury.

Here, we present specific techniques for the ligamentous examination, including identifying injuries of the anterior cruciate ligament (ACL), the medial collateral ligament (MCL), the lateral collateral ligament (LCL), the posterolateral corner (PLC), and the posterior cruciate ligament (PCL), and describe the associated anatomy and biomechanics and the methods that allow for increased diagnostic sensitivity and accuracy.

Anterior Cruciate Ligament

The ACL serves as the primary restraint against anterior tibial translation in the knee. It also provides rotational stability, especially in extension. The ACL originates on the femur at the posteromedial aspect of the lateral femoral condyle (posterolateral femoral notch) and runs anteriorly to its wide tibial insertion at the lateral aspect of the anterior tibial spine. The ACL has two fiber bundles, the anteromedial and posterolateral bundles, which provide varying tension

From the Division of Sports Medicine, Department of Orthopaedics, University of Rochester School of Medicine and Dentistry, Rochester, NY.

Neither of the following authors nor any immediate family member has received anything of value from or has stock or stock options held in a commercial company or institution related directly or indirectly to the subject of this article: Dr. Bronstein and Dr. Schaffer.

The video that accompanies this article is online at <http://links.lww.com/JAAOS/A30>.

J Am Acad Orthop Surg 2017;25:280-287

DOI: 10.5435/JAAOS-D-15-00463

Copyright 2017 by the American Academy of Orthopaedic Surgeons.

from flexion through extension. Injury to the knee ligaments is typically the result of a noncontact change in direction or twisting or landing from a jump. The patient often describes a “pop” that is felt or heard at injury, with the appearance of swelling (ie, hemarthrosis) within a few hours.

Anterior Drawer Test

Clinical instability of the knee associated with ACL injury was described as early as 1845.² Historically, the anterior drawer test has been widely used for the diagnosis of ACL ruptures, but the origin of the test is somewhat obscure. The test has been traced back to an 1875 thesis by George Noulis, who was credited with describing not only the anterior drawer test but also a form of what is now known as the Lachman test.³

The anterior drawer test is performed with the patient supine, the hip flexed at 45°, and the knee flexed at 90°. The foot is fixed to the table (often by sitting on it), and the clinician applies an anterior force to the proximal tibia, palpating the joint line for anterior translation. Increased anterior translation indicates ACL insufficiency. The sensitivity of the anterior drawer test, however, has been reported to be only 50% when performed with the patient under anesthesia because the posterior horn of the medial meniscus may act as a so-called doorstop that prevents anterior translation, even in the presence of a torn ACL⁴ (Figure 1).

Lachman Test

The Lachman test, which was initially described by Torg et al,⁵ is essentially an anterior drawer performed with the knee at 20° to 30° of flexion. It was designed to overcome three identified limitations of the anterior drawer test: (1) acute effusion that often precludes flexion to 90°, (2) protective spasm of the hamstring muscles that can prevent anterior translation of the tibia, and

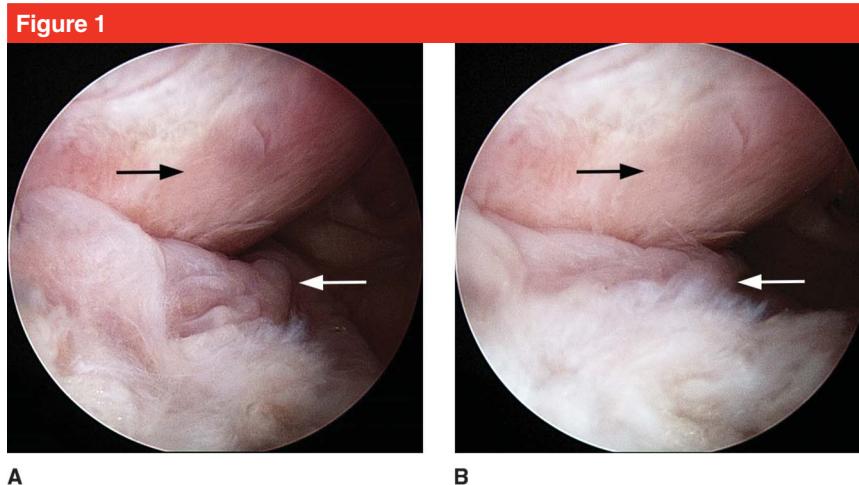


Figure 1
Arthroscopic images of the medial compartment obtained via a posterolateral portal placed in an anterior cruciate ligament–deficient cadaver knee during the anterior drawer test. **A**, The compartment with no application of anterior tibial translatory force. **B**, The compartment with application of anterior tibial translatory force. The posterior horn of the medial meniscus (white arrow) acts as a doorstop, buttressing against the posterior aspect of the medial femoral condyle (black arrow) and preventing anterior translation of the tibia.

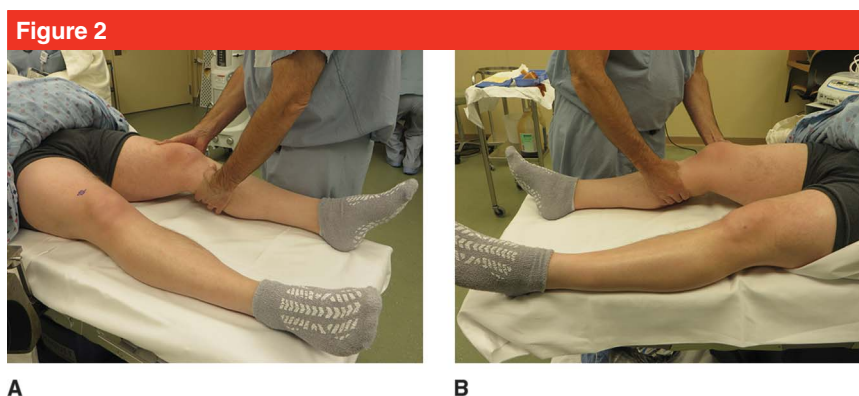
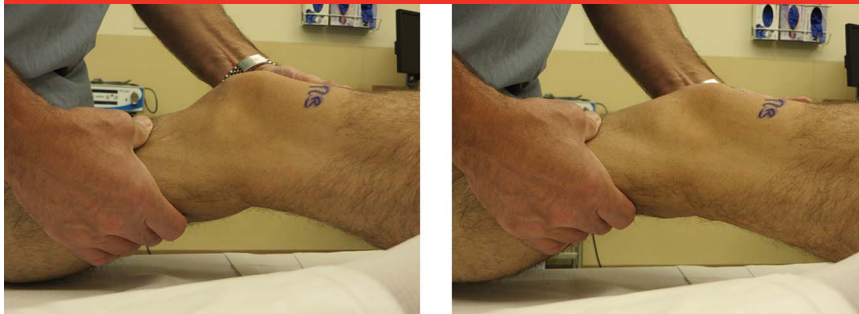


Figure 2
Clinical photographs demonstrating hand positioning for the left knee (**A**) and the right knee (**B**) during the Lachman test. During the test, one hand stabilizes the femur laterally while the other hand, which is placed medially, translates the tibia.

(3) the articulation of the relatively acute convexity of the posterior medial femoral condyle and the posterior horn of the medial meniscus that buttresses and prevents anterior translation of the tibia. These limitations can lead to false-negative findings (See Video, Supplemental Digital Content 1, The Anterior Drawer Test, <http://links.lww.com/JAAOS/A30>). In contrast, the Lachman test, as originally described, was done with the

knee positioned between full extension and 15° flexion.⁵ Currently, the test is typically done with the knee flexed 20° to 30°. The examiner places one hand laterally on the patient’s thigh to stabilize the femur, while the other hand grasps the proximal and more subcutaneous medial tibia and applies anterior stress (Figure 2). The test is positive in the presence of anterior translation and a soft or mushy end point. When the ACL is intact, the end

Figure 3

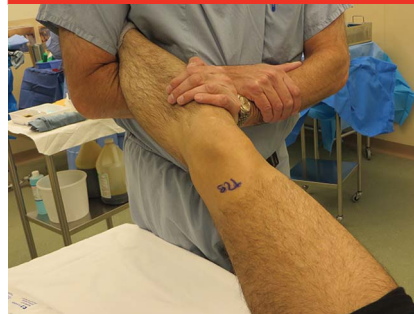

A

B

Clinical photographs demonstrating a positive Lachman examination before (A) and after (B) application of anterior translation.

Figure 4



Clinical photograph demonstrating the authors' preferred positioning for a right knee pivot shift test.

point is hard (Figure 3). With the knee in slight flexion (20° to 30°), the hamstring loses mechanical advantage by simple geometry, and the relatively flat weight-bearing portion of the medial femoral condyle more easily glides over the posterior horn of the medial meniscus. A positive Lachman test is used to grade an injury as 1 (ie, anterior translation >1 to 5 mm compared with the uninjured knee), 2 (ie, anterior translation 6 to 10 mm compared with the uninjured knee), or 3 (ie, anterior translation >10 mm compared with the uninjured knee). These grades are based on objective KT-1000 (arthrometer) measurements but can also be clinically estimated. Any difference between the injured and uninjured side should raise suspicion for an ACL injury. Further classification includes a letter grade of A for a firm or hard end point and a grade of B for a soft end point.

Pivot Shift Test

In 1972, Galway et al⁶ first described the pivot shift as both a clinical phenomenon resulting in the symptom of instability and as a physical sign that can be elicited on examination of the ACL-deficient knee. The pivot shift is characterized by anterior subluxation of the lateral tibial plateau (and concomitant internal rotation of the

tibia) as the knee approaches full extension, and spontaneous reduction as the knee flexes to 30° to 40° . The reduction is achieved by the pull of the iliotibial band as it passes posterior to the axis of the knee.⁷

In the original description of the pivot shift test, the patient is supine with the knee extended. It is essential that the patient is relaxed for this test.^{6,8} The examiner grasps the heel with one hand, pointing the foot upward or with internal rotation, and with the other hand placed over the fibular head, the examiner applies a valgus force through the knee, which impinges the subluxated tibial plateau, preventing too easy a reduction. While the clinician maintains this valgus force and slight internal rotation, the knee is slowly flexed. As it passes 30° to 40° of flexion, the reduction will occur and is often identified by the patient as the instability symptom.^{6,8}

Many modifications to the pivot shift test have been proposed, including incorporation of different positions, modifying rotation, reversing the maneuver, or adding grading systems, but all modifications hinge on the same principle.^{2,8} In our preferred technique for the right knee, the patient is positioned supine, and the examiner grasps the right foot and ankle under the examiner's axilla, crossing the right forearm under the leg and bracing the

hand against the left forearm, which provides slight internal rotation to the leg. The left hand is placed over the proximal fibula and valgus force is applied to the knee (Figure 4). This technique provides a stable base and allows the examiner to slowly flex the knee with great control.

Because the pivot shift test involves applying a valgus stress to the knee, it is important that testing be limited in the setting of a medial injury. The change in the mechanics of the knee with the loss of the medial hinge may affect the reliability of the test, although this phenomenon has not been studied. The examiner must distinguish between a true pivot shift and a reverse pivot shift, which is seen with posterolateral instability in which the tibia reduces in extension and subluxates in flexion.

Novel Tests

Likely because of the strength of the clinical diagnostic ability of the Lachman test, few novel tests have been described since its introduction. One limitation of the Lachman test, however, is the difficulty carrying out the test when the examiner's hands are relatively small compared with the girth of the patient's thigh. Therefore, minor modifications to address this problem were suggested in the late 1980s.^{9,10} Although the Lachman test is used

primarily, two novel tests have been described recently. The loss of extension test is used to measure a loss of maximal passive extension of the knee, which is presumed to be a result of anterior subluxation of the tibia and resultant posterior capsule tightness.¹¹ The lever sign test, or Lelli test, is performed by placing a fist under the calf of the affected leg; this acts as a fulcrum, and a downward force is applied to the quadriceps. Failure of the heel to rise off the table indicates an ACL rupture. In a study of the accuracy of the lever sign test for diagnosis of ACL tears, the lever sign was shown to be more sensitive than other tests (eg, Lachman, anterior drawer, pivot shift) for diagnosis of acute and partial ACL tears.¹²

Diagnostic Accuracy

A meta-analysis of 20 studies of physical examination tests performed in awake patients and those under anesthesia found that, compared with the anterior drawer and pivot shift tests, the Lachman test had the highest sensitivity for detecting acute complete ACL tears in awake patients and in patients under anesthesia (81% and 91%, respectively).¹³ All tests had similar specificity in awake patients. In patients under anesthesia, the pivot shift test was the most specific at 98% (Table 1). These results are in general agreement with an earlier systematic review, which also found that the anterior drawer test had good sensitivity for diagnosis of chronic tears.¹⁴

Medial Collateral Ligament

The MCL is a broad, flat band that consists of superficial and deep components. The superficial MCL (sMCL) originates at the medial femoral epicondyle and inserts onto the medial condyle of the tibia deep to the pes anserinus. The primary function of the sMCL is to resist valgus stress and thus can be injured when a contact or

Table 1

Accuracy of Physical Examination Tests for Diagnosis of Acute Anterior Cruciate Ligament Tears¹³

Test	Awake		With Anesthesia	
	Sensitivity	Specificity	Sensitivity	Specificity
Lachman	0.81	0.81	0.91	0.78
Anterior drawer	0.38	0.81	0.63	0.91
Pivot shift	0.28	0.81	0.73	0.98

noncontact valgus stress is applied to the knee. However, the medial knee structures work together to provide valgus and rotational knee stability, with a close functional relationship between the MCL and the ACL. Thus, the mechanism of injury is frequently a combination of forces that may result in injury to multiple structures.¹⁵ Fetto and Marshall¹⁶ noted that, in grade III MCL injuries, the ACL was disrupted 78% of the time.

The MCL examination begins with palpation. Fairbank¹⁷ noted that MCL sprains typically affect the femoral attachment and are characterized by tenderness at this point. Other structures, however, may cause tenderness in the region of the MCL, including the medial patellofemoral ligament at the medial femoral epicondyle, the joint line at the mid MCL, and pes bursitis or fracture at the distal MCL.

Valgus Stress Test

The competency of the MCL is best assessed with the valgus stress test. Pain or laxity with valgus stress applied through the knee indicates an MCL injury. Additionally, medial pain with valgus stress helps the clinician to differentiate an MCL injury from a medial meniscus tear, which is unloaded with valgus stress. Initially, the valgus stress test was thought to be best carried out with the knee fully extended—this opinion was common into the 1960s¹⁷—however, in the 1950s, articles began noting that instability in full extension required injury to the sMCL, the deep MCL

(dMCL), and at least one cruciate ligament.^{18,19} In an anatomic study published in 1965, Hallén and Lindahl²⁰ showed that any number of ligaments could be cut without compromising valgus stability in full extension as long as the posterior capsule and femoral and tibial condyles were intact. At 20° of flexion, however, successive division of the sMCL, dMCL, ACL, and PCL produced increasing laxity.

Fetto and Marshall¹⁶ developed a classification system for valgus laxity measured at 0° and 30°, with grade I denoting tenderness with stability at both angles, grade II denoting laxity at 30°, and grade III denoting laxity at both 0° and 30°. One advantage of this system is that it follows the biomechanics of the medial knee: at 30°, the sMCL is the primary restraint to valgus stress, whereas at 0° the posterior oblique ligament and posterior medial corner complex are the primary restraints.¹⁵ Currently, no classification system has been validated or is consistently used for outcomes reporting.

We perform the valgus stress test first with the knee fully extended and then with the knee slightly flexed (approximately 20° to 30°), which relaxes the posterior capsule and helps to isolate the MCL. When valgus stress is applied, laxity, the amount of medial joint opening, and the quality of the end point, should be assessed. A great deal of normal variation in laxity exists, so it is essential to compare the laxity of the

injured knee with that of the contralateral knee. Valgus instability in full extension indicates tearing of the dMCL, sMCL, and at least one cruciate ligament.¹⁵

Radiography can be used as an adjunct to valgus stress testing, helping the clinician to quantify the degree of medial joint line opening. In practice, this is rarely done; however, if laxity to valgus stress is seen in the setting of open physes, stress radiography must be performed to distinguish between an MCL injury and a nondisplaced physal fracture.

Anteromedial Drawer Test

The anteromedial drawer test is another tool that can be used to assess abnormal medial compartment rotation and anterior translation. The knee is flexed 90° with the foot internally rotated and fixed at 15°, while an anterior force is applied to the tibia. This test helps to isolate the posterior oblique ligament and posteromedial capsule. Asymmetric increased translation indicates a significant injury to these structures.¹⁵

Lateral Collateral Ligament and Posterolateral Corner

The LCL is a narrow cordlike band that originates slightly proximal and posterior to the lateral femoral epicondyle and inserts on the medial fibular head, deep to the biceps femoris tendon. The primary function of the LCL is to resist varus stress. It can easily be directly palpated by flexing the knee to 90° and resting the ankle on the contralateral leg to form the figure-4 position. This position places varus stress on the knee and opens the lateral joint line, allowing the examiner to palpate the intact taut ligament. Fairbank¹⁷ noted that LCL sprains typically affect the fibular attachment, and tenderness might localize there. Gross laxity under varus load can be assessed by

reversing the previously described valgus stress test. Like the MCL, the LCL is best isolated at 30° flexion, and the varus stress test should likewise be performed at both 0° and 30° flexion. Laxity at 0° indicates more severe injury, including injury to not only the LCL, but also to the PLC and/or associated cruciate ligaments.^{21,22}

Unlike tears of the MCL, isolated LCL tears are relatively rare but often accompany injury to the posterolateral structures. Aside from the LCL, the main structures of the PLC are the popliteus tendon and the popliteofibular ligament. In addition, the lateral capsule and sometimes the arcuate ligament and the fabellofibular ligament provide static stability, whereas the biceps femoris, popliteus muscle, iliotibial tract, and the lateral head of the gastrocnemius provide dynamic stability. The primary function of these structures is to provide rotary stability. Isolated PLC injuries are rare, accounting for <2% of all knee ligament injuries,²³ and most PLC injuries occur in the setting of multiligamentous injuries, which are as high as 87%.²⁴ Despite being relatively rare, PLC injuries carry significant morbidity and, therefore, must be quickly recognized. Twenty-five percent of PLC injuries are associated with peroneal nerve injuries,²⁵ and failure to recognize and/or treat the PLC injuries has been shown to increase the failure rates of ACL and PCL reconstructions.²⁶⁻²⁸

Varus Thrust Gait

LaPrade and Wentorf²⁹ described the posterolateral injury as one of the most debilitating injuries to the knee because, in the absence of the posterolateral static stabilizers, the convex opposing surfaces of the lateral tibial plateau and femoral condyles can cause lateral compartment opening even in normal gait. This varus thrust gait, in which the knee joint is sub-

luxated in varus upon foot strike, may be readily noted on examination, particularly in the setting of chronic instability. However, the examiner should be careful to consider that some patients may have learned to compensate with a flexed knee gait pattern or may have an underlying varus knee deformity with medial compartment collapse rather than lateral opening, which can obscure the physical examination findings.²⁹

Several special tests, including the external rotation recurvatum, posterolateral rotary drawer, and dial tests, are used to evaluate the PLC and assess rotatory instability, which can be subtle and requires careful attention. No single test is diagnostic in itself, and accurate evaluation of the PLC requires a careful history as well as a combination of tests.

External Rotation Recurvatum Test

The external rotation recurvatum test is the most basic special test for PLC injury. The examiner supports the relaxed lower extremity by the great toe and examines the position of the knee. Relative hyperextension (which can be measured with a goniometer or heel-height comparison), tibial external rotation, and knee varus alignment compared with the contralateral side may indicate PLC injury.³⁰ The sensitivity of this test ranges from 33% to 94%.³¹

Posterolateral Rotary Drawer Test

The posterolateral rotary drawer test and the dial test are the two most commonly used special tests for PLC evaluation. First described by Hughston and Norwood³⁰ in 1980, the posterolateral rotary drawer test is a variation of the standard posterior drawer test for PCL evaluation. With the knee flexed to 90°, the hip flexed to 45°, and the foot fixed in slight external rotation (usually best at

¹⁵³¹), a posteriorly directed force is applied through the tibial tuberosity.²² The PCL is relaxed in this position, allowing rotary and translatory laxity. Furthermore, this position places the PCL in a more direct anterior-to-posterior orientation, focusing its function on translatory stability. The key point is to quantify the ratio of translation to rotation and to compare this ratio to the ratio obtained from the same test done with the knee in neutral rotation. With an isolated PLC injury, there will be more rotatory instability seen with slight external rotation than with neutral rotation because the PCL provides more translational stability with neutral rotation. With an isolated PCL injury, more translatory instability than rotary instability will be present.²¹

Dial Test

The examiner can use the dial test to determine the amount of external rotation of the tibia on the femur, which helps the examiner to differentiate an isolated PLC injury from a combined PLC and PCL injury. The test must be done with the patient in the prone position, which allows simultaneous bilateral testing and provides a good opportunity to visually examine the posterior knee for complications, such as ecchymosis and swelling. To perform the test, both knees are flexed first to 30° (which best isolates the PLC), then to 90°, with external rotation applied to the tibias at each position. The examiner compares the injured side with the uninjured side. The feet, with the ankles fully dorsiflexed to minimize laxity, are used as a marker for tibial rotation. The use of the thigh-foot angle runs the risk of overestimation of the true tibial angle, but, because the aim of the dial test is only to provide a side-to-side comparison, if the examiner assumes similar laxity in the bilateral ankles, the difference should remain

true. Veltri and Warren³² showed that a 10° increase in external rotation at 30° knee flexion (compared with the contralateral side) was abnormal and indicated a PLC injury. A dial test that is positive (ie, 10° increased external rotation) at 30° but not at 90° indicates isolated PLC injury. If the test is positive at 90°, there is a concomitant injury to the PCL or to the PCL and the medial structures.³³ A recent clinical study investigated the reliability of the dial test using a handheld inclinometer with the patient in the supine position.³⁴ The authors found that, for side-to-side comparison, a difference of >15° was required for clinical significance.³⁴ Notably, Jung et al³⁵ showed that, in knees with combined PCL-PLC injuries and resting posterior subluxation, application of an anteriorly directed force to reduce the subluxation resulted in approximately 6° increased external rotation at both 30° and 90° knee flexion.

Standing Apprehension Test

Ferrari et al³⁶ described the use of the standing apprehension test to detect posterolateral instability of the knee. The patient stands with the knee slightly bent and internally rotates the torso away from the leg, producing an internal rotation of the femur on the tibia. If the patient experiences apprehension or instability, the test is considered positive. The authors considered the test to be 100% sensitive, but this estimation was based on a small patient cohort, and all of the patients had positive dial tests at 90° knee flexion, indicating injury to the PCL and PLC.

Posterior Cruciate Ligament

The PCL is the primary restraint to posterior tibial translation. Its femoral insertion is a broad, vertically oriented footprint at the anterolateral

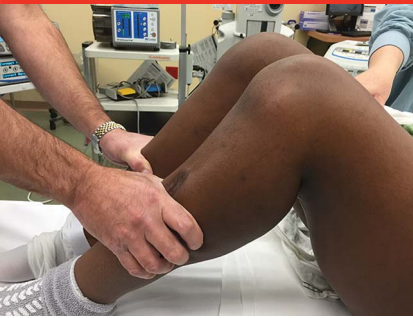aspect of the medial femoral condyle. The PCL runs posterolaterally toward the central posterior aspect of the tibia, inserting on its own fovea approximately 1 cm distal to the joint line, just posterior to the posterior horn of the medial meniscus. The PCL is made up of the anterolateral and the posteromedial fiber bundles.³⁷

As previously noted, injuries to the PLC tend to be high energy, and as many as 87% of injuries are multiligamentous.²⁴ Furthermore, 95% of PCL injuries diagnosed in emergency departments are associated with multiligamentous injuries.³⁸ A commonly described mechanism of injury is striking the tibia on the dashboard during a motor vehicle collision. Isolated PCL injuries also are seen in athletic competition when the athlete falls directly onto the knee with the foot plantar flexed, allowing the tibial tuberosity to strike the ground. However, the injury can be caused by both hyperflexion and hyperextension.³⁹ Isolated PCL injuries are often undiagnosed because the classic popping sound at injury is not as distinctive and the swelling is not as severe as that associated with ACL injuries, and recurrent instability is rare.⁴⁰

The posterior drawer test and the quadriceps active test are used for diagnosis of PCL tears. Each test is performed with the hip flexed to 45° and the knee flexed to 90°. In this position, there is a loss of the normal anterior tibial step-off with a PCL injury.³¹ Typically, when the knee is flexed to 90°, the anteromedial tibial plateau extends 1 cm anteriorly beyond the medial femoral condyle.³

Posterior Sag Sign

The posterior sag sign can be used to assess for loss of anterior tibial step-off, without any manipulation of the joint.³ A randomized, controlled,

Figure 5

Clinical photograph demonstrating a positive posterior drawer test in the left knee. Note the increased posterior translation compared with that of the contralateral side.

blinded study of chronic tears reported that the sensitivity and specificity of this test was 79% and 100%, respectively.⁴¹

Posterior Drawer Test

The posterior drawer test essentially adds a posteriorly directed force to the posterior sag sign. The foot is positioned in neutral rotation (versus the slight external rotation in the posterolateral rotary drawer test). The examiner then immobilizes the foot (often by sitting on it), places the thumbs on the tibial plateau, and pushes posteriorly on the tibia to assess for increased translation compared with the contralateral side (Figure 5). Some studies have found the posterior drawer test sensitivity to be as low as 51%⁴² or 55%³⁰ in the setting of acute PCL tears, but other studies report a sensitivity of 90% and a specificity of 99% in the setting of chronic tears.⁴¹ Malanga et al³ found that, although many studies have reported on the accuracy of the posterior drawer test, those studies had flaws in sample size or methodology, and the authors concluded that the posterior drawer test is highly sensitive and specific (more so in chronic than in acute tears) and that the utility of the test

is increased when combined with a complete knee examination. If increased posterior translation relative to the uninjured knee is observed and the tibia remains anterior to the femoral condyles, the posterior drawer result is rated 1+. When the tibia is even with the femoral condyles, the posterior drawer result is rated 2+, and when the tibia drops behind the femoral condyles, the test is graded 3+.

Quadriceps Active Test

The quadriceps active test was described by Daniel et al.⁴³ The patient position for this test is the same as that for the posterior drawer test, but the patient is asked to slightly contract the quadriceps rather than having the examiner apply force. In a PCL-deficient knee placed in the resting 90° flexion position, the tibia is subluxated posteriorly, but activation of the quadriceps causes the patellar tendon to reduce the tibia. This observable reduction constitutes a positive test result. Daniel et al⁴³ reported a 98% sensitivity and 100% specificity for the quadriceps active test, but their study was unblinded and nonrandomized. In a randomized controlled blinded study, Rubinstein et al⁴¹ reported that the test had a sensitivity and specificity of 54% and 97%, respectively. These differences are attributable both to methodology and patient population; however, compared with the other previously mentioned tests, the quadriceps active test may be less sensitive. Because the quadriceps active test begins with a positive posterior drawer result, we have found it to be redundant.

Summary

With a thorough history and physical examination, a clinician can accu-

rately and efficiently diagnose a variety of knee pathologies, including ligamentous injuries. Radiographs should be obtained in any case of knee injury. MRI, which may be helpful in certain cases, is not always necessary and should not be obtained in place of a thorough history and physical examination.

References

Evidence-based Medicine: Levels of evidence are described in the table of contents. In this article, references 35 and 41 are level I studies. References 4, 5, 10, 11, 13, 14, 24, and 43 are level II studies. References 12, 16, and 34 are level III studies. References 3, 6, 8, 9, 22, 23, 25, 36, 38, 39, and 42 are level IV studies. References 1, 2, 7, 15, 17, 18, 21, 26-33, and 40 are level V expert opinion.

References printed in **bold type** are those published within the past 5 years.

1. Shelbourne KD: The art of the knee examination: Where has it gone? *J Bone Joint Surg Am* 2010;92(9):e9.
2. Lane CG, Warren R, Pearle AD: The pivot shift. *J Am Acad Orthop Surg* 2008;16(12):679-688.
3. Malanga GA, Andrus S, Nadler SF, McLean J: Physical examination of the knee: A review of the original test description and scientific validity of common orthopedic tests. *Arch Phys Med Rehabil* 2003;84(4):592-603.
4. DeHaven KE: Diagnosis of acute knee injuries with hemarthrosis. *Am J Sports Med* 1980;8(1):9-14.
5. Torg JS, Conrad W, Kalen V: Clinical diagnosis of anterior cruciate ligament instability in the athlete. *Am J Sports Med* 1976;4(2):84-93.
6. Galway RD, Beauprey A, MacIntosh DL: Pivot shift: A clinical sign of anterior cruciate insufficiency. *J Bone Joint Surg Br* 1972;54B:763.
7. Slocum DB, James SL, Larson RL, Singer KM: Clinical test for anterolateral rotary instability of the knee. *Clin Orthop Relat Res* 1976;118:63-69.
8. Galway HR, MacIntosh DL: The lateral pivot shift: A symptom and sign of anterior

- cruciate ligament insufficiency. *Clin Orthop Relat Res* 1980;147:45-50.
9. Wroble RR, Lindenfeld TN: The stabilized Lachman test. *Clin Orthop Relat Res* 1988; 237:209-212.
 10. Adler GG, Hoekman RA, Beach DM: Drop leg Lachman test: A new test of anterior knee laxity. *Am J Sports Med* 1995;23(3): 320-323.
 11. Salvi M, Caputo F, Piu G, Sanna M, Sanna C, Marongiu G: The loss of extension test (LOE test): A new clinical sign for the anterior cruciate ligament insufficient knee. *J Orthop Traumatol* 2013;14(3):185-191.
 12. Lelli A, Di Turi RP, Spenciner DB, Domini M: The "Lever Sign": A new clinical test for the diagnosis of anterior cruciate ligament rupture. *Knee Surg Sports Traumatol Arthrosc* 2016;24(9):2794-2797
 13. van Eck CF, van den Bekerom MP, Fu FH, Poolman RW, Kerkhoffs GM: Methods to diagnose acute anterior cruciate ligament rupture: A meta-analysis of physical examinations with and without anaesthesia. *Knee Surg Sports Traumatol Arthrosc* 2013;21(8):1895-1903.
 14. Benjaminse A, Gokeler A, van der Schans CP: Clinical diagnosis of an anterior cruciate ligament rupture: A meta-analysis. *J Orthop Sports Phys Ther* 2006;36(5): 267-288.
 15. Bollier M, Smith PA: Anterior cruciate ligament and medial collateral ligament injuries. *J Knee Surg* 2014;27(5):359-368.
 16. Fetto JF, Marshall JL: Medial collateral ligament injuries of the knee: A rationale for treatment. *Clin Orthop Relat Res* 1978; 132:206-218.
 17. Fairbank TJ: Examination of the knee joint. *Br Med J* 1969;3(5664):220-222.
 18. De Palma AF: *Diseases of the Knee: Management in Medicine and Surgery*. Philadelphia, Lippincott, 1954.
 19. Palmer I: Pathophysiology of the medical ligament of the knee joint. *Acta Chir Scand* 1958;115(4):312-318.
 20. Hallén LG, Lindahl O: The lateral stability of the knee-joint. *Acta Orthop Scand* 1965; 36(2):179-191.
 21. Devitt BM, Whelan DB: Physical examination and imaging of the lateral collateral ligament and posterolateral corner of the knee. *Sports Med Arthrosc* 2015;23(1):10-16.
 22. Hughston JC, Andrews JR, Cross MJ, Moschi A: Classification of knee ligament instabilities: Part II. The lateral compartment. *J Bone Joint Surg Am* 1976; 58(2):173-179.
 23. DeLee JC, Riley MB, Rockwood CA Jr: Acute posterolateral rotatory instability of the knee. *Am J Sports Med* 1983;11(4): 199-207.
 24. LaPrade RF, Wentorf FA, Fritts H, Gundry C, Hightower CD: A prospective magnetic resonance imaging study of the incidence of posterolateral and multiple ligament injuries in acute knee injuries presenting with a hemarthrosis. *Arthroscopy* 2007;23 (12):1341-1347.
 25. Becker EH, Watson JD, Drees JC: Investigation of multiligamentous knee injury patterns with associated injuries presenting at a level I trauma center. *J Orthop Trauma* 2013;27(4):226-231.
 26. LaPrade RF, Resig S, Wentorf F, Lewis JL: The effects of grade III posterolateral knee complex injuries on anterior cruciate ligament graft force: A biomechanical analysis. *Am J Sports Med* 1999;27(4): 469-475.
 27. LaPrade RF, Muench C, Wentorf F, Lewis JL: The effect of injury to the posterolateral structures of the knee on force in a posterior cruciate ligament graft: A biomechanical study. *Am J Sports Med* 2002;30(2): 233-238.
 28. Harner CD, Vogrin TM, Höher J, Ma CB, Woo SL: Biomechanical analysis of a posterior cruciate ligament reconstruction: Deficiency of the posterolateral structures as a cause of graft failure. *Am J Sports Med* 2000;28(1):32-39.
 29. LaPrade RF, Wentorf F: Diagnosis and treatment of posterolateral knee injuries. *Clin Orthop Relat Res* 2002;402:110-121.
 30. Hughston JC, Norwood LA Jr: The posterolateral drawer test and external rotational recurvatum test for posterolateral rotatory instability of the knee. *Clin Orthop Relat Res* 1980;147: 82-87.
 31. Larsen MW, Toth A: Examination of posterolateral corner injuries. *J Knee Surg* 2005;18(2):146-150.
 32. Veltri DM, Warren RF: Anatomy, biomechanics, and physical findings in posterolateral knee instability. *Clin Sports Med* 1994;13(3):599-614.
 33. Veltri DM, Deng XH, Torzilli PA, Warren RF, Maynard MJ: The role of the cruciate and posterolateral ligaments in stability of the knee: A biomechanical study. *Am J Sports Med* 1995;23(4):436-443.
 34. Krause DA, Levy BA, Shah JP, Stuart MJ, Hollman JH, Dahm DL: Reliability of the dial test using a handheld inclinometer. *Knee Surg Sports Traumatol Arthrosc* 2013;21(5): 1011-1016.
 35. Jung YB, Lee YS, Jung HJ, Nam CH: Evaluation of posterolateral rotatory knee instability using the dial test according to tibial positioning. *Arthroscopy* 2009;25(3): 257-261.
 36. Ferrari DA, Ferrari JD, Coumas J: Posterolateral instability of the knee. *J Bone Joint Surg Br* 1994;76(2):187-192.
 37. Edwards A, Bull AM, Amis AA: The attachments of the fiber bundles of the posterior cruciate ligament: An anatomic study. *Arthroscopy* 2007;23(3):284-290.
 38. Fanelli GC, Edson CJ: Posterior cruciate ligament injuries in trauma patients: Part II. *Arthroscopy* 1995;11(5):526-529.
 39. Fowler PJ, Messieh SS: Isolated posterior cruciate ligament injuries in athletes. *Am J Sports Med* 1987;15(6):553-557.
 40. Lee BK, Nam SW: Rupture of posterior cruciate ligament: Diagnosis and treatment principles. *Knee Surg Relat Res* 2011;23(3): 135-141.
 41. Rubinstein RA Jr, Shelbourne KD, McCarroll JR, VanMeter CD, Rettig AC: The accuracy of the clinical examination in the setting of posterior cruciate ligament injuries. *Am J Sports Med* 1994;22(4): 550-557.
 42. Loos WC, Fox JM, Blazina ME, Del Pizzo W, Friedman MJ: Acute posterior cruciate ligament injuries. *Am J Sports Med* 1981;9 (2):86-92.
 43. Daniel DM, Stone ML, Barnett P, Sachs R: Use of the quadriceps active test to diagnose posterior cruciate-ligament disruption and measure posterior laxity of the knee. *J Bone Joint Surg Am* 1988;70 (3):386-391.